

Spared Perception of the Structure of Scenes after Hippocampal Damage

Zhisen J. Urgolites^{1,2}, Ramona O. Hopkins^{3,4}, and Larry R. Squire^{1,2}

Abstract

■ To explore whether the hippocampus might be important for certain spatial operations in addition to its well-known role in memory, we administered two tasks in which participants judged whether objects embedded in scenes or whether scenes themselves could exist in 3-D space. Patients with damage limited to the hippocampus performed as well as controls in both tasks. A patient with large medial-temporal lobe lesions had a bias to judge objects in scenes and scenes themselves as possible, performing well with possible stimuli but poorly with impossible

stimuli in both tasks. All patients were markedly impaired at remembering the tasks. The hippocampus appears not to be essential for judging the structural coherence of objects in scenes or the coherence of scenes. The findings conform to what is now a sizeable literature emphasizing the importance of the hippocampus for memory. We discuss our results in light of findings that other patients have sometimes been reported to be disadvantaged by spatial tasks like the ones studied here, despite less hippocampal damage and milder memory impairment. ■

INTRODUCTION

The hippocampus is essential for the formation of long-term declarative memory (Eichenbaum & Cohen, 2004; Squire, 1992). Some studies have suggested that the hippocampus might also be important for certain spatial operations. Thus, hippocampal lesions impaired the ability to construct scenes, perceive scenes, or shift perspective (Maguire & Mullally, 2013; Mullally, Intraub, & Maguire, 2012; Graham, Barense, & Lee, 2010; Hartley et al., 2007; King, Burgess, Hartley, Vargha-Khadem, & O'Keefe, 2002). Yet, for many of these studies, performance may have required the support of long-term memory (i.e., because the memory load exceeded the capacity of working memory) or the task allowed for a contribution from long-term memory (because the same stimuli were repeated across trials). In these circumstances, patients with hippocampal lesions might have been disadvantaged due to their memory impairment. In our own studies of spatial tasks, where we attempted to minimize the contribution of long-term memory (by limiting the number of stimuli or by using trial-unique stimuli), hippocampal patients performed as well as controls (path integration, Kim, Sapiurka, Clark, & Squire, 2013; Shrager, Kirwan, & Squire, 2008; visual discrimination of scenes, Kim et al., 2011; spatial imagery, Kim, Borst, et al., 2013; scene construction, Kim, Dede, Hopkins, & Squire, 2015; map reading and navigation, Urgolites, Kim, Hopkins, &

Squire, 2016; topographical memory with shifts of viewpoint, Urgolites, Hopkins, & Squire, 2017; scene construction with shifts of viewpoint, Rungratsameetaweemana & Squire, 2018). For a report of impaired performance in a task using trial-unique stimuli, see Lee et al. (2005).

Other studies have used trial-unique, single items and asked for judgments about whether an object or scene can exist in 3-D space (possible/impossible decision tasks; Urgolites, Levy, Hopkins, & Squire, 2018; Douglas et al., 2017; McCormick, Rosenthal, Miller, & Maguire, 2017; Lee & Rudebeck, 2010). For objects, two studies found intact performance in patients with lesions limited to the hippocampus (Urgolites et al., 2018; Lee & Rudebeck, 2010). Patients with larger medial-temporal lobe (MTL) lesions were impaired. In a different study involving scenes, patients with lesions reportedly limited to the hippocampus were impaired at making possible/impossible judgments about structural coherence (McCormick et al., 2017). The difficulty appeared to involve particularly the ability to identify impossible scenes. In addition, a neuroimaging study found greater activity in the hippocampus than in the parahippocampal cortex when individuals viewed impossible scenes (and vice versa when individuals viewed possible scenes; Douglas et al., 2017).

Interestingly, the same patients who were impaired at making possible/impossible judgments about the structural coherence of scenes were intact at making semantic judgments about scenes (i.e., whether scenes represented possible or impossible content; McCormick et al., 2017). Thus, the patients had no difficulty with scene perception itself. Their difficulty seemed related specifically to the appreciation of geometric structure.

¹Veterans Affairs San Diego Healthcare System, ²University of California, San Diego, ³Brigham Young University, ⁴Intermountain Medical Center, Murray, UT

Moreover, this difficulty involved the structural coherence of scenes, not objects, because judgments about the structural coherence of objects were intact after hippocampal lesions (Urgolites et al., 2018; Lee & Rudebeck, 2010).

To investigate the role of the hippocampus in appreciating the structural coherence of scenes, we administered two possible/impossible tasks to four patients with circumscribed hippocampal lesions and one patient with large, well-characterized MTL lesions. The object-in-scene decision task presented possible and impossible objects that were embedded in scenes, and the scene decision task presented possible and impossible scenes. The first task used the same pictures of objects that patients previously judged successfully as being possible or impossible (Urgolites et al., 2018), but now these objects were embedded in scenes. The purpose here was to ask whether objects presented in the context of a scene would be judged differently than when the same objects were presented in isolation as in our earlier study (Urgolites et al., 2018). The second task presented possible and impossible scenes in an attempt to match the task used by McCormick et al. (2017). In addition to asking for judgments about scenes, we also tested memory. We asked participants to recollect details about the first task and to remember the scenes that were presented in the second task.

METHODS

Participants

Five memory-impaired patients participated, four with bilateral lesions thought to be limited to the hippocampus (CA fields, dentate gyrus, and subicular complex) and one with larger MTL lesions (Table 1). Patient D. A. became amnesic in 2011 following a drug overdose and associated respiratory failure. K. E. became amnesic in 2004 after an episode of ischemia associated with kidney failure and toxic shock syndrome. L. J. (the only woman) became amnesic during a 6-month period in 1988 with no known precipitating event. Her memory impairment

has been stable since that time. G. P. has severe memory impairment resulting from viral encephalitis in 1987. J. R. W. became amnesic in 1990 following an anoxic episode associated with cardiac arrest.

Estimates of MTL damage were based on quantitative analysis of magnetic resonance images from 19 age-matched, healthy men for K. E., J. R. W., and G. P., 11 age-matched, healthy women for patient L. J. (Gold & Squire, 2005), and 8 younger healthy men for D. A. Patients D. A., K. E., L. J., and J. R. W. have an average bilateral reduction in hippocampal volume of 35%, 49%, 46%, and 44%, respectively (mean = 43.5%, all values at least 2.9 SDs from the control mean). On the basis of two patients (L. M. and W. H.) with similar bilateral volume loss in the hippocampus for whom detailed postmortem neurohistological information was obtained (Rempel-Clover, Zola, Squire, & Amaral, 1996), the degree of volume loss in the four hippocampal patients may reflect nearly complete loss of hippocampal neurons. The volume of the parahippocampal gyrus (temporopolar, perirhinal, entorhinal, and parahippocampal cortices) is reduced by -5%, 11%, -17%, and 12%, respectively (all values within 2 SDs of the control mean). The negative values indicate volumes that were larger for a patient than for controls. These values are based on published guidelines for identifying the boundaries of the parahippocampal gyrus (Frankó, Insausti, Artacho-Pérula, Insausti, & Chavoix, 2014; Insausti et al., 1998). Additional measurements, based on four controls for each patient, were carried out for the insular cortex, fusiform gyrus, frontal, lateral, temporal, parietal, and occipital lobes, both gray and white matter (all volumes within 1.3 SDs of the control means; Bayley, Gold, Hopkins, & Squire, 2005).

G. P. has an average bilateral reduction in hippocampal volume of 96%. The volume of the parahippocampal gyrus is reduced by 94%. G. P. also has a reduction of 24% (> 3 SDs below control mean) in the left lateral temporal lobe (mostly anterior and ventral) and a reduction of 6% (< 1 SD below control mean) in the right temporal lobe. The volumes of the lateral temporal lobes were calculated for G. P. and 14 age-matched controls using

Table 1. Characteristics of Memory-impaired Patients

Patient	Age (years)	Education (years)	WAIS-III IQ	WMS-R				
				Attention	Verbal	Visual	General	Delay
D. A.	35	12	95	104	90	91	90	56
K. E.	77	13.5	108	114	64	84	72	55
L. J.	81	12	101	105	83	60	69	<50
J. R. W.	55	12	90	87	65	95	70	<50
G. P.	72	16	98	102	79	62	66	50

The WAIS-III is the Wechsler Adult Intelligence Scale-III, and the WMS-R is the Wechsler Memory Scale-Revised. The WMS-R does not provide numerical scores for individuals who score <50. The IQ score for D. A. is from the WAIS-IV.

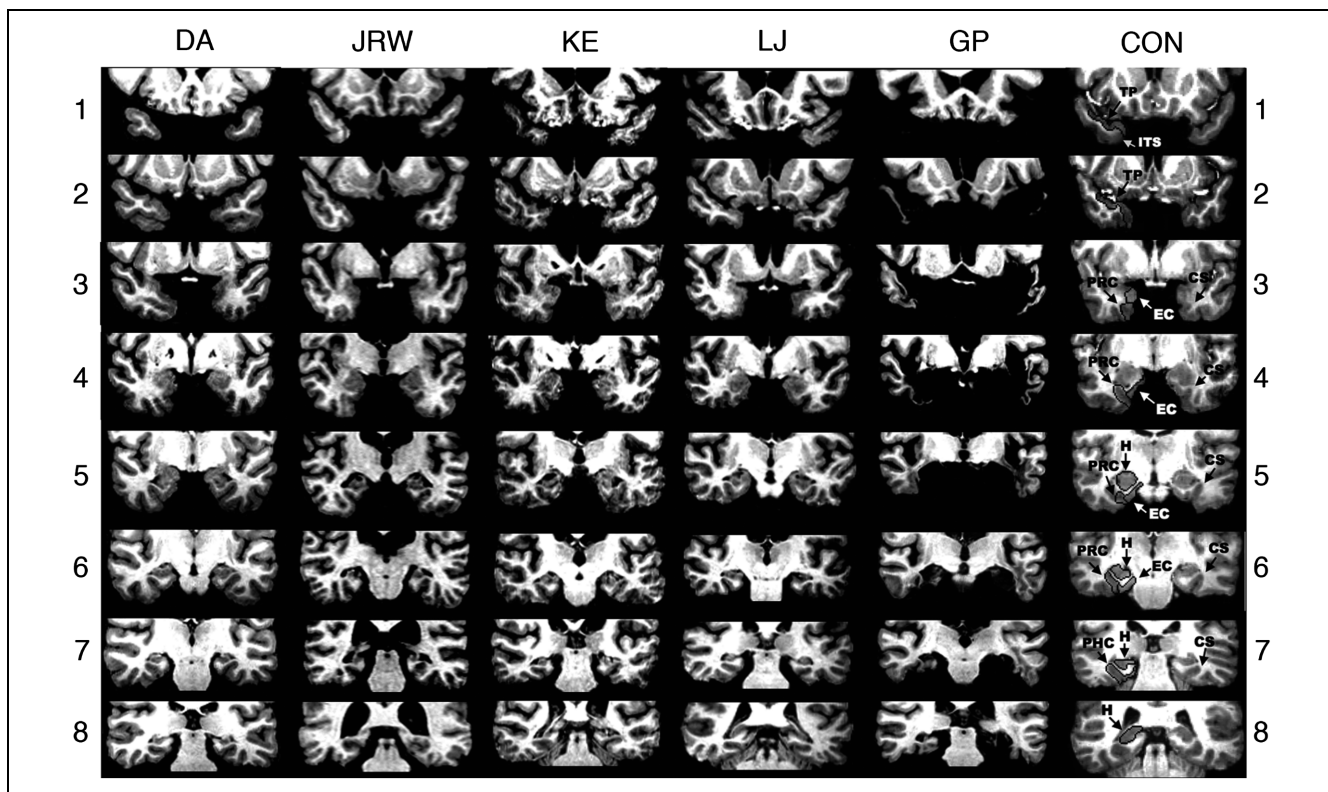


Figure 1. Magnetic resonance brain images. A series of eight T1-weighted coronal images are illustrated for four patients with limited hippocampal lesions (D. A., J. R. W., K. E., and L. J.), one patient with extensive MTL damage (G. P.), and one control (CON). The sections proceed posteriorly in 7-mm intervals from the temporopolar (TP) cortex in the top section. The left side of the brain is on the right side of each image. As described in Insausti et al. (1998), TP cortex extends medially from the inferotemporal sulcus (ITS) to the fundus of the TP sulcus. TP cortex extends rostrally from the tip of the temporal pole caudally to the limen insula (LI), which approximates the border between the TP cortex and perirhinal cortex (PRC). Caudal to TP cortex, the collateral sulcus (CS) is the most important structure for the identification of MTL cortices. At its most rostral extent, the CS is surrounded entirely by PRC. Caudally, entorhinal cortex (EC) extends from the midpoint of the medial bank of the CS to the subiculum, whereas PRC extends laterally from the midpoint of the medial bank of the CS to the inferotemporal cortex. Two millimeters caudal to the disappearance of the gyrus intralimbicus of the hippocampus (H), the CS is surrounded by parahippocampal cortex (PHC). The caudal border of the posterior PHC is defined as lying 1.5 mm posterior to the crus of the fornix at the point where the fimbria turns upward to continue as the posterior pillars of the fornix and posterior to the pulvinar nucleus of the thalamus (Frankó et al., 2014). The top section (1) shows the TP cortex and the ITS in the control brain. None of the patients with limited hippocampal lesions has damage evident at this level. For G. P., the TP cortex and lateral temporal cortex are missing bilaterally. The ITS is visible bilaterally for patients J. R. W. and K. E. For L. J., only the right ITS is visible. For D. A., the ITS is not visible on either side at this level. The second section (2) shows TP cortex and the ITS in the control brain. The ITS and TP cortex is evident in all patients with limited hippocampal lesions at this level. None of the patients with limited hippocampal lesions has damage evident at this level. For G. P., note that the portion of the temporal lobe missing corresponds to TP cortex and also involves the lateral temporal lobe, especially on the left. The CS is visible, indicating the beginning of PRC, in patients K. E. (right side only). The third section (3) shows the CS and surrounding PRC and EC in the control brain. None of the patients with limited hippocampal lesions has damage evident at this level with the exception of K. E., who has damage in the BG secondary to toxic shock syndrome (and to a lesser extent in Section 4). For patient D. A., the CS is not evident at this level, and PRC is evident bilaterally. For patients K. E. and L. J., the PRC is evident on the left side, bounded by the LI and CS. On the right side, both EC and PRC are evident. For patient J. R. W., both EC and PRC are evident bilaterally. For G. P., no CS or surrounding tissue is evident, and damage to left lateral temporal lobe is evident. The fourth section (4) shows the anterior hippocampus and the adjacent PRC and EC in the control brain. At this level, hippocampal damage is evident in patient D. A. The hippocampus is not yet visible at this level in any of the other patients with limited hippocampal lesions. For D. A., bilateral damage to the globus pallidus is evident at this level, presumably secondary to heroin overdose. No damage to the PRC or EC is evident for any of the patients at this level, except for G. P., who has no MTL tissue at this level and who has damage to the left lateral temporal lobe. The fifth section (5) shows the hippocampus and the adjacent PRC and EC in the control brain. The CS and the surrounding PRC and EC appear normal in all patients at this level with the exception of G. P., who has no MTL tissue at this level and who exhibits some damage to left lateral temporal lobe. Damage is evident in the hippocampal region of all patients. The sixth section (6) shows the hippocampus and the adjacent PRC and EC in the control brain. Damage is evident in the hippocampal region for all patients at this level. The surrounding PRC and EC appear normal in all patients except G. P., who has little normal MTL tissue in either hemisphere. Both the PRC and EC are visible in all hippocampal patients bilaterally, with the exception of J. R. W. for whom only PRC is visible on the left side, indicated by the disappearance of the gyrus intralimbicus 2 mm rostral to the sixth section (not shown). The seventh section (7) shows the hippocampus and the CS, surrounded by PHC in the control brain. Damage to the hippocampus is evident in all patients at this level. In all patients with damage limited to the hippocampus, the PHC is evident, but in patient D. A., the PRC is still visible on the right side. Patient G. P. has little normal MTL tissue in either hemisphere. The eighth section (8) shows the hippocampus in the control brain. Bilateral hippocampal damage is evident in patients D. A., K. E., and G. P. at this level. Patient L. J. shows hippocampal damage only on the left side. At this level, the hippocampus is no longer evident in patient J. R. W. PHC is no longer evident at this level in patients D. A., J. R. W., K. E., or L. J. Patient G. P. has some spared PHC on the right at this level. Posterior to this level, G. P. exhibits hippocampal damage and damage to the PHC. No damage is evident posterior to this level for any of the other patients.

FreeSurfer software (Version 5.1; Fischl et al., 2002, 2004; Dale, Fischl, & Sereno, 1999; Fischl, Sereno, & Dale, 1999). The temporal lobe measures included gray matter and associated white matter in the fusiform, inferior temporal, middle temporal, and superior temporal gyri. The volumes were adjusted with respect to intracranial volume as calculated by FreeSurfer (estimated total intracranial volume; Buckner et al., 2004). Manual intervention was carried out to correct errors associated with boundaries between the brain and pia/skull and boundaries between gray matter and white matter. Figure 1 shows eight coronal magnetic resonance images from each patient, together with detailed descriptions of the lesions.

For the five patients, the average score for delayed recall (30 min) of two short prose passages (Wechsler Memory Scale-Revised) was 1.4 segments (1.5 for the four hippocampal patients and 1.0 for G. P.; 25 segments per passage). The average score for delayed recall (10–15 min) of a complex diagram (Osterrieth, 1944) was 5.5 (5.9 for the four hippocampal patients and 4.0 for G. P.; maximum score = 36). Paired-associate learning of 10 unrelated noun-

noun pairs summed across each of three successive learning trials was 5.0 pairs (6.3 for the four hippocampal patients and 0 for G. P.; maximum score = 30). On these same tests, 11 healthy controls averaged 20.2 for the two prose passages, 18.3 for the diagram, and 24.1 for paired-associate learning (Smith, Frascino, Hopkins, & Squire, 2013).

Nine healthy controls (two women) also participated (mean age = $66.6\% \pm 4.7\%$ years; mean education = $14.0\% \pm 0.7\%$ years). All procedures were approved by the institutional review board at the VA San Diego Healthcare System, and participants gave written informed consent before participation. All participants took an object-in-scene decision task and a scene decision task on the same day. Each task was followed by a memory test that asked about the task.

Materials and Procedure

In the object-in-scene decision task, participants judged whether an object could or could not exist in 3-D space.

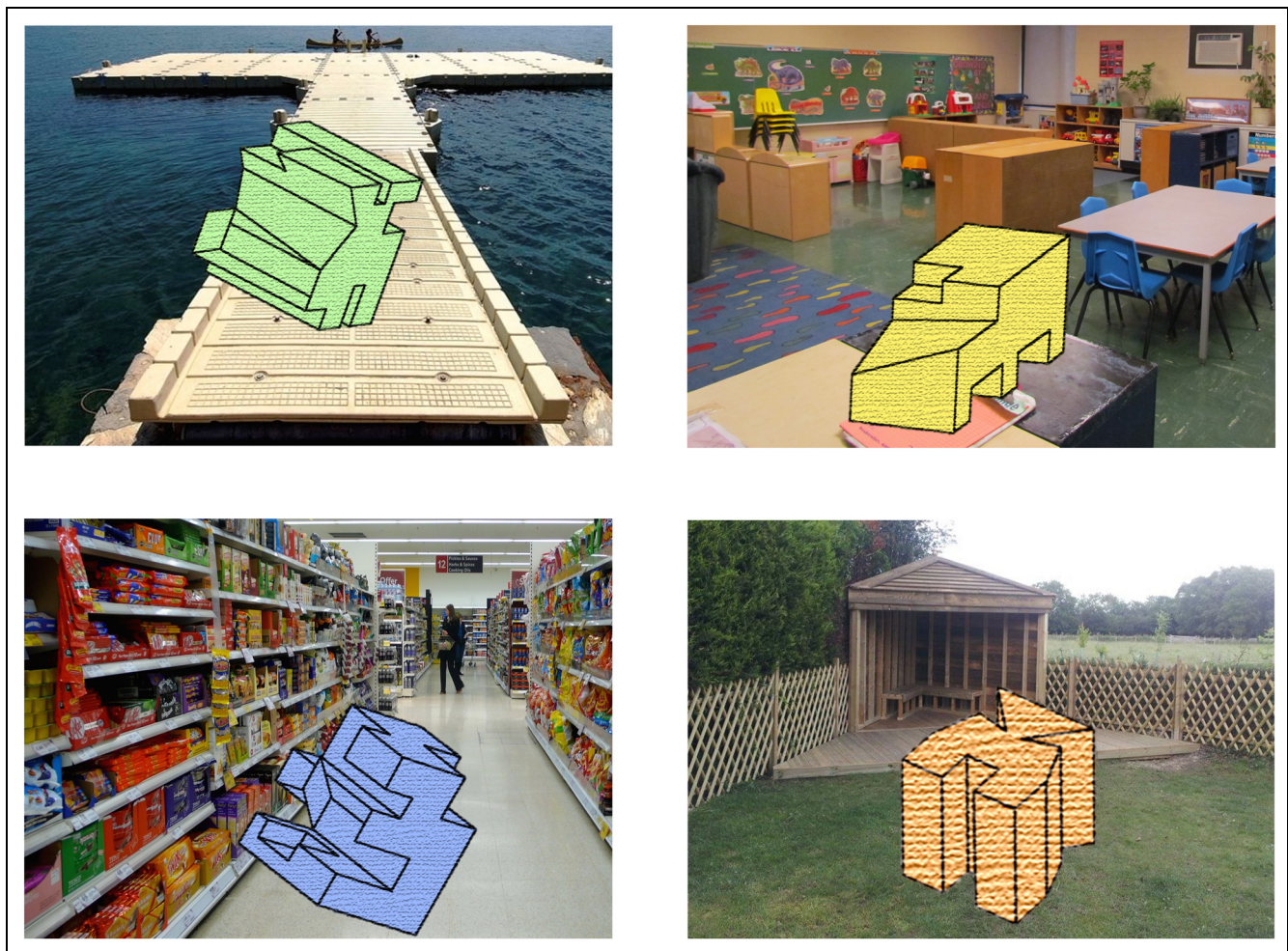


Figure 2. Sample items from the object-in-scene decision task. On each trial, participants decided whether the object in the scene could or could not exist in 3-D space (i.e., “possible” or “impossible”). The objects on the left depict impossible objects, and the objects on the right depict possible objects.

The stimuli consisted of drawings of 40 possible and 40 impossible objects, termed “sculptures,” each of which was embedded in a scene (Figure 2). The objects were originally black-and-white line drawings of unfamiliar objects (Urgolites et al., 2018), with color and texture added (using Microsoft PowerPoint, Version 16.16 for color and Adobe Photoshop CS6 for texture). Eleven additional object-in-scene stimuli were also created. Six were used to explain the task (three possible and three impossible objects), and five were used as practice trials with feedback (three possible and two impossible objects). Following the practice trials, participants saw the 80 object-in-scene stimuli one at a time on a computer screen (visual angle = $20.8^\circ \times 12.4^\circ$). The words “impossible” and “possible” appeared at the left and right below each scene, and participants pressed a key at the left or right side of a keyboard to indicate their choices. The scenes were presented in a random order with the constraint that no more than three possible or impossible scenes were presented consecutively. Testing was self-paced without feedback. Immediately afterward, memory was tested by asking 8 three-alternative, forced-choice questions about the nature of the task (Table 2).

In the scene decision task, given next, participants judged whether a scene could or could not exist in 3-D space. The stimuli consisted of pictures of 23 possible and 23 impossible scenes (Figure 3). The scenes were selected to be as similar as possible to the scenes presented as samples by McCormick et al. (2017) and to contain the same sorts of structural violations as in their descriptions. One of their sample scenes (the triangle that appear in

their Figure 1) was also a scene in our study. For our study, 10 additional scenes were also available, half as samples to explain the task (two possible and three impossible scenes) and half as material for practice trials (three possible and two impossible scenes). Following the practice trials (with feedback), participants saw the 46 scenes one at a time on a computer screen (visual angle = $11.0^\circ \times 8.3^\circ$ for 9 vertically oriented scenes and $8.3^\circ \times 11.0^\circ$ for 14 horizontally oriented scenes). The procedure in this experiment was the same as in the object-in-scene task.

Immediately afterward, participants took an old/new recognition memory test consisting of 18 novel scenes that had not been presented and 18 old scenes that had been presented as part of the task (nine possible and nine impossible in each case). Participants saw these 36 scenes one at a time on a computer screen (visual angles were the same as in the decision task), and they pressed one of two keys to indicate whether the scene was “new” or “old.” Scenes were presented in a random order with the constraint that no more than three new scenes or three old scenes appeared consecutively. Testing was self-paced without feedback.

RESULTS

The Object-in-scene Decision Task

The patients with hippocampal damage performed overall as well as controls ($d' = 2.5\% \pm 0.4\%$ vs. $2.6\% \pm 0.3\%$, $t(11) = 0.12$, $p = .905$, independent t test; accuracy, $87.2\% \pm 4.7\%$ correct vs. $86.3\% \pm 3.0\%$ correct, $t(11) = 0.17$, $p = .870$,

Table 2. Factual Questions about the Object-in-scene Decision Task

No.	Questions	Choices
1	How many practice items did you work on before you took the real test?	2, 5, or 10
2	How did you receive feedback about being correct or incorrect during the practice?	Text on the computer, orally by the experimenter, or both
3	In the instructions, how did I refer to the object in the scene?	As a shape, as a structure, or as a sculpture
4	After the practice, which key was pressed to start the real test?	Space bar, enter, or tab
5	How many pictures were presented during the real test?	20–30, 50–60, or 80–90
6	How were the instructions presented?	Orally by the experimenter, on the screen, or both
7	What color was the text that appeared on the screen?	Red, black, or blue
8	What happened after you pressed a key to give your response in the test?	A white screen appeared before the next scene came up, the next scene came up immediately, or a black screen appeared before the next scene came up



Figure 3. Sample items from the scene decision task. Participants decided whether each scene could or could not exist in 3-D space (i.e., “possible” or “impossible”). The pictures on the left depict impossible scenes and the pictures on the right depict possible scenes.

independent *t* test; Figure 4A, B). The patients were adept at detecting the impossible objects in scenes (patients = 90.0%, 85.0%, 95.0%, and 95.0% correct; mean = 91.3% ± 2.4% correct; control mean, 87.5% ± 3.2% correct) as well as the possible objects in scenes (patients = 57.5%, 90.0%, 95.0%, 90.0% correct; mean = 83.1% ± 8.6% correct; control mean, 85.0% ± 5.3% correct).

In contrast, the patient with large MTL lesions was impaired ($d' = 1.5$ vs. 2.6% ± 0.3%, $t(8) = 3.45$, $p = .009$, one-sample *t* test; accuracy, 77.5% correct vs. 86.3% ± 3.0% correct, $t(8) = 2.96$, $p = .018$, one-sample *t* test; Figure 4A, B). His difficulty was specifically in detecting the impossible objects in scenes: 72.5% correct for the

MTL patient versus 87.5% ± 3.2% correct for controls, $t(3) = 7.83$, $p = .004$, one-sample *t* test. Possible objects in scenes presented no difficulty: 82.5% correct versus 85.0% ± 5.3% correct. RTs were similar across the three groups (Figure 4C), and there was no evidence of response bias (Figure 4D).

The Scene Decision Task

The hippocampal patients performed overall as well as controls ($d' = 2.1$ ± 0.3% vs. 2.6% ± 0.4%, $t(11) = 0.96$, $p = .357$, independent *t* test; accuracy, 83.2% ± 3.4% correct vs. 87.9% ± 3.5% correct, $t(11) = 0.82$, $p = .430$,

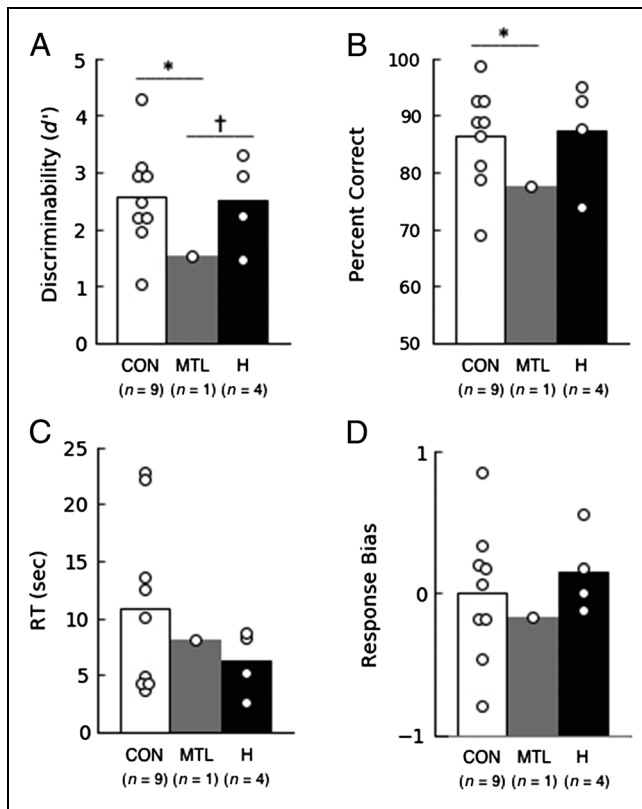


Figure 4. Performance on the object-in-scene decision task. (A, B) Patients with damage limited to the hippocampus performed similarly to controls, but the patient with large MTL lesions was impaired. The three groups had similar RTs (C) and exhibited no response bias (D). CON = control; H = hippocampal patients; MTL = the MTL patient. * $p \leq .018$. † $p = .093$.

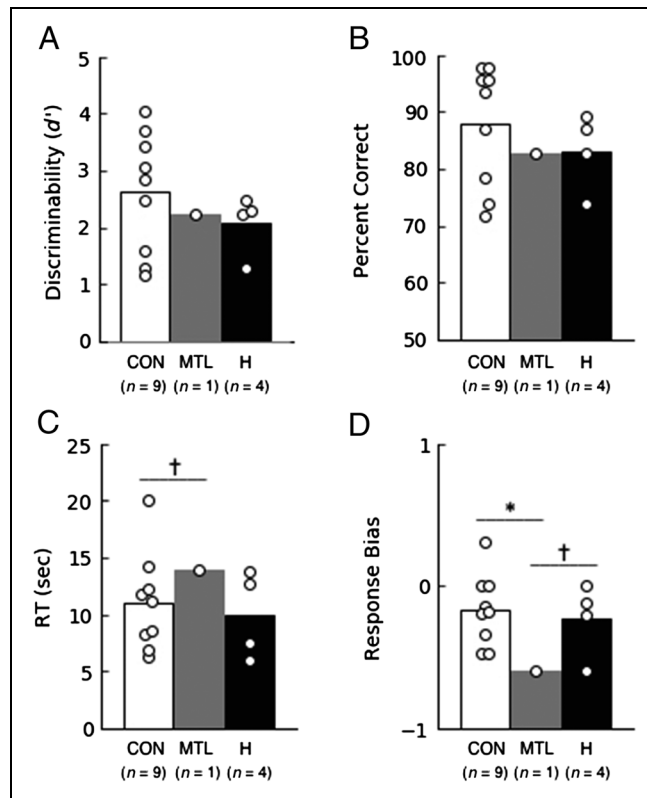


Figure 5. Performance on the scene decision task. (A, B) Both the patients with damage limited to the hippocampus and the patient with large MTL lesions performed similarly to controls. The MTL patient responded a little slowly (C) and also had a strong tendency to judge the scenes as possible (D). CON = control; H = hippocampal patients; MTL = the MTL patient. * $p = .001$. † $p \leq .077$.

independent t test; Figure 5A, B). The patients were adept at detecting impossible scenes (patients = 87.0%, 73.9%, 69.6%, and 82.6% correct; mean = 78.3% \pm 4.0% correct; control mean = 85.5% \pm 4.3% correct) and possible scenes (patients = 91.3%, 73.9%, 95.7%, 91.3% correct; mean = 88.0% \pm 4.8% correct; control mean = 90.3% \pm 3.1% correct; $p > .326$, independent t tests).

The MTL patient performed well overall ($d' = 2.2$ vs. 2.6 ± 0.4 , $t(8) = 1.51$, $p = .170$, one-sample t test; accuracy, 82.6% correct vs. $87.9\% \pm 3.5\%$ correct, $t(8) = 1.13$, $p = .293$, one-sample t test; Figure 5A, B). However, he had a bias to judge scenes as possible (see below). Thus, he obtained a very good score on the possible scenes (MTL, 95.7% correct; controls, $90.3\% \pm 3.1\%$ correct) but scored poorly on the impossible scenes (MTL, 69.6% correct; controls, $85.5\% \pm 4.3\%$ correct; $t(8) = 3.71$, $p = .006$, one-sample t test). We note too that the patients scored well in the scene depicting a triangle (patients, 75.0% correct; controls, 77.8% correct), which was also a test item in the earlier study (Figure 1 of McCormick et al., 2017).

The hippocampal patients and controls had similar RTs, but the MTL patient was marginally slower than the controls (13.9 sec vs. $11.0\% \pm 1.4\%$ sec, $t(8) = 2.03$, $p = .077$, one-sample t test; Figure 5C). The MTL

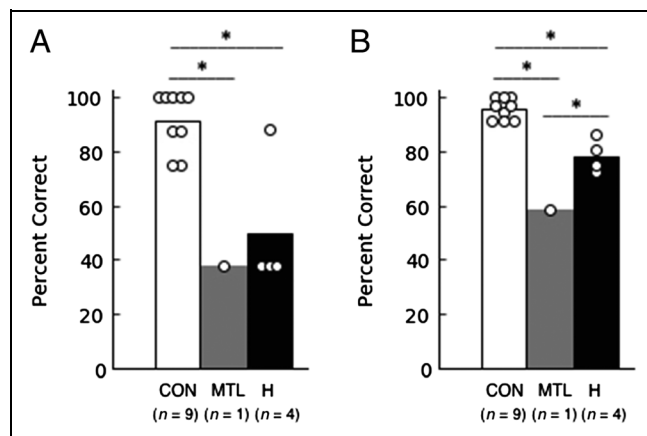


Figure 6. Performance on memory tests for the two tasks. Both the hippocampal patients and the MTL patient were impaired at remembering facts about the object-in-scene decision task (A). Both the hippocampal patients and the MTL patient were also impaired at recognizing the scenes that had been presented in the scene decision task. The MTL patient was more impaired than the hippocampal patients (B). CON = control; H = hippocampal patients; MTL = the MTL patient. * $p \leq .039$.

patient had a bias (Response Bias $C = -0.60$) to judge the scenes as possible and a stronger bias than controls (MTL vs. controls, $t(8) = 5.18$, $p = .001$, one-sample t test; Figure 5D).

Memory Tests

Each of the two tasks was followed by a memory test about the task. For the object-in-scene decision task, the hippocampal patients and the MTL patient were markedly impaired at remembering facts about the task (hippocampal patients, $50.0\% \pm 12.5\%$ correct; MTL, 37.5% correct; controls, $91.6\% \pm 3.6\%$ correct; $ps \leq .039$, independent t test and one-sample t test; Figure 6A, chance = 33.3%). Memory for the second task was assessed by a recognition memory test based on scenes presented during the task. Both patient groups were impaired (Figure 6B; hippocampal patients, $78.4\% \pm 5.2\%$ correct, $d' = 1.6\% \pm 0.2\%$; MTL, 58.3% correct, $d' = 0.4$; controls, $96.0\% \pm 1.2\%$ correct, $d' = 3.9\% \pm 0.2\%$; $ps < .001$, independent t test and one-sample t test). The MTL patient was more impaired than the hippocampal patients (accuracy, $t(3) = 6.54$, $p = .007$; d' , $t(3) = 5.28$, $p = .013$; one-sample t tests).

DISCUSSION

In both the object-in-scene decision task and the scene decision task, hippocampal patients performed as well as controls (Figures 4 and 5). The same result was reported in two related studies in which participants judged whether drawings of single objects were possible or impossible (Urgolites et al., 2018; Lee & Rudebeck, 2010). Thus, in these studies, lesions limited to the hippocampus did not affect the ability to judge the structural coherence of objects, objects embedded in scenes, or scenes themselves. This conclusion is in accord with our earlier findings that the hippocampus is also not needed for a variety of other spatial tasks, so long as the tasks do not depend on long-term memory (Rungratsameetaweemana & Squire, 2018; Urgolites et al., 2016, 2017; Kim et al., 2011, 2015; Kim, Borst, et al., 2013; Kim, Sapiurka, et al., 2013; Shrager et al., 2008).

Patient G. P. with large MTL lesions obtained a moderately impaired score in the object-in-scene decision task (Figure 4) and a good overall score on the scene decision task (Figure 5). Note that, on the object-in-scene task, G. P. had a strong bias to judge scenes as possible. One hippocampal patient had a similar bias.

In the memory tests (Figure 6), both the hippocampal patients and G. P. were markedly impaired at remembering facts about the object-in-scene task and at remembering the scenes that had been presented in the scene decision task.

Our findings differ from the findings reported in an earlier study of a similar task in which six patients with

hippocampal lesions were impaired at detecting impossible scenes (McCormick et al., 2017). These six patients had developed their condition following an episode of voltage-gated potassium channel complex antibody-mediated limbic encephalitis. Intriguingly, this impairment occurred despite the fact that the six patients had less severe hippocampal damage than our four hippocampal patients (mean 19.8% reduction in hippocampal volume bilaterally vs. mean 43.5% reduction) and also less severe memory impairment than our patients.

To evaluate memory, we compared the two patient groups on three different memory tests: word recognition, delayed prose recall, and delayed diagram recall (scores for patients in McCormick et al., 2017, come from Table 2 of McCormick, Rosenthal, Miller, & Maguire, 2018, which involved the same six patients). First, patients in the earlier study were intact at word recognition (scaled score = 12.3 for patients and 12.0 for controls; Warrington, 1984), whereas our four hippocampal patients were impaired on the same test (scaled score = 7.3 for the hippocampal patients and 13.5 for controls). Second, patients in the earlier study obtained a scaled score of 7.8 for delayed recall of two prose passages from the Wechsler Memory Scale-III, whereas the scaled score for our four patients on a nearly identical test was 1.8 (Wechsler Memory Scale-Revised). Third, patients in the earlier study obtained a score of 18.1 of 36 points for delayed recall of a complex figure (Osterrieth, 1944), whereas the score for our patients was 5.9. (We recognize that, for this third test, the score for our patients might have been better if they had also taken a recall test immediately after copying the figure, as the patients in the earlier study did.) In any case, the situation is that, in two groups of patients, the group with larger hippocampal lesions and more severe memory impairment was intact at the scene decision task, whereas the group with smaller lesions and a milder memory deficit was impaired. What might explain this pattern of results?

One possibility is that characteristics of the patients are significant. The patients in the earlier study of scene decision (McCormick et al., 2017) had limbic encephalitis, whereas most of the patients participating in our studies of human hippocampal function developed memory impairment as the result of ischemia or anoxia. Limbic encephalitis is a complex disorder that can have acute and chronic cognitive effects, for example, reduced IQ scores, in addition to memory impairment (Miller et al., 2017; Dalmau & Rosenfeld, 2014; Vincent et al., 2004). Nevertheless, the condition follows a variable course, and some patients do well. Indeed, neuropsychological testing of the patient group selected for the study of scenes (McCormick et al., 2017) found no evidence of cognitive impairment outside memory.

A related possibility is that different etiologies (limbic encephalitis and anoxia/ischemia) are associated with damage in different locations within the hippocampus and that this has functional significance. One report of

18 patients found focal atrophy of hippocampal subfield CA3 following limbic encephalitis (Miller et al., 2017). In contrast, lesions associated with anoxia/ischemia especially target areas CA1, CA2, and the dentate gyrus across the full rostrocaudal extent of the hippocampus (Zola-Morgan, Squire, Rempel, Clower, & Amaral, 1992). However, anoxia/ischemia can also result in nearly complete loss of hippocampal neurons (Rempel-Clower et al., 1996). Additional neurohistological study of these conditions might be fruitful.

Another possibility turns on the methods used to characterize the extent of brain damage. For the study finding impaired scene decision (McCormick et al., 2017), a group comparison method (i.e., voxel-based morphometry) was used to identify consistent differences between patients and controls in brain regions outside the hippocampus. No differences in gray matter were detected between groups. However, this method identifies significant brain damage in a patient group only when damage occurs in the same locations. It is possible that limbic encephalitis causes damage outside the hippocampus and that the damaged regions do not overlap across patients. Quantification of the volume of individual brain regions in individual patients (as was done by McCormick et al. for the hippocampus) is a more sensitive method of detecting brain damage. One wants to know what damage has occurred in individual patients, not just what damage is common to all patients.

A final point of interest is that the six patients in the earlier study of scene decision did not all exhibit an impairment in identifying impossible scenes. Three were fully intact, performing well within the range of control scores (Figure 3 of McCormick et al., 2017). The three other patients were impaired at detecting impossible scenes, performing well outside the range of control scores. The scores of these three patients, as estimated from Figure 3 of McCormick et al. (60%, 64%, and 64% correct), were lower than the scores for impossible scenes obtained by any of the four patients in our hippocampal group (87.0%, 82.6%, 73.9%, and 69.6% correct; $p = .023$, independent t test). Indeed, the three patients in the earlier study who were impaired performed numerically worse on impossible scenes than even our patient G. P. (69.6% correct) who has large MTL lesions as well as volume loss of the left temporal lobe. It is not known whether the three patients in the earlier study who did poorly might differ in the extent of hippocampal damage from the three who did well. Perhaps a small impairment on the scene decision task (Cohen's $d = 0.9$, as reported in the earlier study) can result from variable effects of limbic encephalitis on brain regions outside the hippocampus. Such an idea is consistent with the findings reported here for hippocampal patients with a different etiology, who performed well on the scene decision task despite having larger hippocampal lesions and a more severe memory impairment than the patients studied by McCormick et al. (2017). We

encourage others to explore this and related spatial tasks, particularly in relation to the etiology of the study patients, to try to identify conditions that demonstrate an impairment.

Acknowledgments

This work was supported by the Medical Research Service of the Department of Veterans Affairs (5IK6CX001644), award I01CX000359, and National Institute of Mental Health Grant 24600. We thank Jennifer Frascino for assistance and Christine Smith and Chih-Ying Su for comments on earlier versions of the article.

Reprint requests should be sent to Larry R. Squire, Veterans Affairs San Diego Healthcare System, 3550 La Jolla Village Drive, 116A, San Diego, CA 92161, or via e-mail: lsquire@ucsd.edu.

REFERENCES

- Bayley, P. J., Gold, J. J., Hopkins, R. O., & Squire, L. R. (2005). The neuroanatomy of remote memory. *Neuron*, *46*, 799–810.
- Buckner, R. L., Head, D., Parker, J., Fotenos, A. F., Marcus, D., Morris, J. C., et al. (2004). A unified approach for morphometric and functional data analysis in young, old, and demented adults using automated atlas-based head size normalization: Reliability and validation against manual measurement of total intracranial volume. *Neuroimage*, *23*, 724–738.
- Dale, A. M., Fischl, B., & Sereno, M. I. (1999). Cortical surface-based analysis: I. Segmentation and surface reconstruction. *Neuroimage*, *9*, 179–194.
- Dalmau, J., & Rosenfeld, M. R. (2014). Autoimmune encephalitis update. *Neuro-Oncology*, *16*, 771–778.
- Douglas, D., Thavabalasingam, S., Chorghay, Z., O'Neil, E. B., Barense, M. D., & Lee, A. C. H. (2017). Perception of impossible scenes reveals differential hippocampal and parahippocampal place area contributions to spatial coherency. *Hippocampus*, *27*, 61–76.
- Eichenbaum, H., & Cohen, N. J. (2004). *From conditioning to conscious recollection: Memory systems of the brain*. New York: Oxford University Press.
- Fischl, B., Salat, D. H., Busa, E., Albert, M., Dieterich, M., Haselgrove, C., et al. (2002). Whole brain segmentation: Automated labeling of neuroanatomical structures in the human brain. *Neuron*, *33*, 341–355.
- Fischl, B., Sereno, M. I., & Dale, A. M. (1999). Cortical surface-based analysis: II. Inflation, flattening, and a surface-based coordinate system. *Neuroimage*, *9*, 195–207.
- Fischl, B., van der Kouwe, A., Destrieux, C., Halgren, E., Ségonne, F., Salat, D. H., et al. (2004). Automatically parcellating the human cerebral cortex. *Cerebral Cortex*, *14*, 11–22.
- Frankó, E., Insausti, A. M., Artacho-Péruña, E., Insausti, R., & Chavoix, C. (2014). Identification of the human medial temporal lobe regions on magnetic resonance images. *Human Brain Mapping*, *35*, 248–256.
- Gold, J. J., & Squire, L. R. (2005). Quantifying medial temporal lobe damage in memory-impaired patients. *Hippocampus*, *15*, 79–85.
- Graham, K. S., Barense, M. D., & Lee, A. C. H. (2010). Going beyond LTM in the MTL: A synthesis of neuropsychological and neuroimaging findings on the role of the medial temporal lobe in memory and perception. *Neuropsychologia*, *48*, 831–853.
- Hartley, T., Bird, C. M., Chan, D., Cipolotti, L., Husain, M., Vargha-Khadem, F., et al. (2007). The hippocampus is

- required for short-term topographical memory in humans. *Hippocampus*, *17*, 34–48.
- Insausti, R., Juottonen, K., Soininen, H., Insausti, A. M., Partanen, K., Vainio, P., et al. (1998). MR volumetric analysis of the human entorhinal, perirhinal, and temporopolar cortices. *American Journal of Neuroradiology*, *19*, 659–671.
- Kim, S., Borst, G., Thompson, W. L., Hopkins, R. O., Kosslyn, S. M., & Squire, L. R. (2013). Sparing of spatial mental imagery in patients with hippocampal lesions. *Learning & Memory*, *20*, 657–663.
- Kim, S., Dede, A. J. O., Hopkins, R. O., & Squire, L. R. (2015). Memory, scene construction, and the human hippocampus. *Proceedings of the National Academy of Sciences, U.S.A.*, *112*, 4767–4772.
- Kim, S., Jeneson, A., van der Horst, A. S., Frascino, J. C., Hopkins, R. O., & Squire, L. R. (2011). Memory, visual discrimination performance, and the human hippocampus. *Journal of Neuroscience*, *31*, 2624–2629.
- Kim, S., Sapiurka, M., Clark, R. E., & Squire, L. R. (2013). Contrasting effects on path integration after hippocampal damage in humans and rats. *Proceedings of the National Academy of Sciences, U.S.A.*, *110*, 4732–4737.
- King, J. A., Burgess, N., Hartley, T., Vargha-Khadem, F., & O'Keefe, J. (2002). Human hippocampus and viewpoint dependence in spatial memory. *Hippocampus*, *12*, 811–820.
- Lee, A. C. H., Buckley, M. J., Pegman, S. J., Spiers, H., Scahill, V. L., Gaffan, D., et al. (2005). Specialization in the medial temporal lobe for processing of objects and scenes. *Hippocampus*, *15*, 782–797.
- Lee, A. C. H., & Rudebeck, S. R. (2010). Human medial temporal lobe damage can disrupt the perception of single objects. *Journal of Neuroscience*, *30*, 6588–6594.
- Maguire, E. A., & Mullally, S. L. (2013). The hippocampus: A manifesto for change. *Journal of Experimental Psychology: General*, *142*, 1180–1189.
- McCormick, C., Rosenthal, C. R., Miller, T. D., & Maguire, E. A. (2017). Deciding what is possible and impossible following hippocampal damage in humans. *Hippocampus*, *27*, 303–314.
- McCormick, C., Rosenthal, C. R., Miller, T. D., & Maguire, E. A. (2018). Mind-wandering in people with hippocampal damage. *Journal of Neuroscience*, *38*, 2745–2754.
- Miller, T. D., Chong, T. T.-J., Aimola Davies, A. M., Ng, T. W. C., Johnson, M. R., Irani, S. R., et al. (2017). Focal CA3 hippocampal subfield atrophy following LGI1 VGKC-complex antibody limbic encephalitis. *Brain*, *140*, 1212–1219.
- Mullally, S. L., Intraub, H., & Maguire, E. A. (2012). Attenuated boundary extension produces a paradoxical memory advantage in amnesic patients. *Current Biology*, *22*, 261–268.
- Osterrieth, P. A. (1944). Le test de copie d'une figure complexe; contribution à l'étude de la perception et de la mémoire [Test of copying a complex figure; contribution to the study of perception and memory]. *Archives de Psychologie*, *30*, 206–356.
- Rempel-Clower, N. L., Zola, S. M., Squire, L. R., & Amaral, D. G. (1996). Three cases of enduring memory impairment after bilateral damage limited to the hippocampal formation. *Journal of Neuroscience*, *16*, 5233–5255.
- Rungratsameetaweemana, N., & Squire, L. R. (2018). Preserved capacity for scene construction and shifts in perspective after hippocampal lesions. *Learning & Memory*, *25*, 347–351.
- Shrager, Y., Kirwan, C. B., & Squire, L. R. (2008). Neural basis of the cognitive map: Path integration does not require hippocampus or entorhinal cortex. *Proceedings of the National Academy of Sciences, U.S.A.*, *105*, 12034–12038.
- Smith, C. N., Frascino, J. C., Hopkins, R. O., & Squire, L. R. (2013). The nature of anterograde and retrograde memory impairment after damage to the medial temporal lobe. *Neuropsychologia*, *51*, 2709–2714.
- Squire, L. R. (1992). Memory and the hippocampus: A synthesis from findings with rats, monkeys, and humans. *Psychological Review*, *99*, 195–231.
- Urgolites, Z. J., Hopkins, R. O., & Squire, L. R. (2017). Medial temporal lobe and topographical memory. *Proceedings of the National Academy of Sciences, U.S.A.*, *114*, 8626–8630.
- Urgolites, Z. J., Kim, S., Hopkins, R. O., & Squire, L. R. (2016). Map reading, navigating from maps, and the medial temporal lobe. *Proceedings of the National Academy of Sciences, U.S.A.*, *113*, 14289–14293.
- Urgolites, Z. J., Levy, D. A., Hopkins, R. O., & Squire, L. R. (2018). Spared perception of object geometry and object components after hippocampal damage. *Learning & Memory*, *25*, 330–334.
- Vincent, A., Buckley, C., Schott, J. M., Baker, I., Dewar, B.-K., Detert, N., et al. (2004). Potassium channel antibody-associated encephalopathy: A potentially immunotherapy-responsive form of limbic encephalitis. *Brain*, *127*, 701–712.
- Warrington, E. K. (1984). *Recognition memory test*. Windsor, United Kingdom: NFER-Nelson.
- Zola-Morgan, S., Squire, L. R., Rempel, N. L., Clower, R. P., & Amaral, D. G. (1992). Enduring memory impairment in monkeys after ischemic damage to the hippocampus. *Journal of Neuroscience*, *12*, 2582–2596.